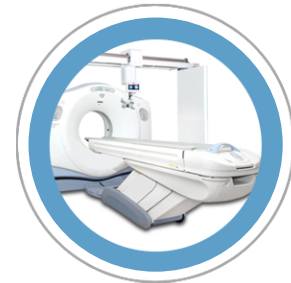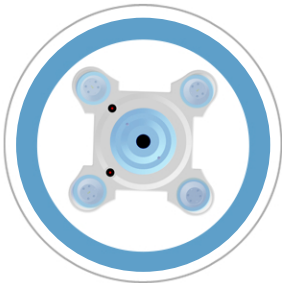



HIGNOON



Shadow Based Needle Navigation CT Interventions Made Easy

vTitan Corporation Private Limited

New Woodlands Block, Estancia IT Park,
Plot No. 140 & 151, GST Road,
Vallancherry Village,
Chengalpattu 603 202, India.
Toll Free Number: 18005721664

www.vtitan.com

sales@vtitan.com

©2025 vTitan Corporation Pvt. Ltd.
980-1041 Rev 08

India's first shadow based, CT guided instrument positioning assistant, which helps clinicians in performing high-risk and high-precision percutaneous medical interventions.

Why HighNoon?

In any CT guided intervention, accuracy of needle placement, which influences diagnostic yield/ treatment success, is highly dependent upon physician skill and experience. Vulnerable anatomy in proximity to the target has low tolerance for needle injury.

With conventional techniques, challenging targets frequently mandate multiple needle adjustments and intra-procedural imaging, which can prolong procedure duration and increase pain, patient radiation exposure and procedural risk.

How HighNoon overcomes these challenges?

Complete Procedural Control

- User friendly planning station
- Simple, shadow based, real time guidance
- Confirm instrument placement

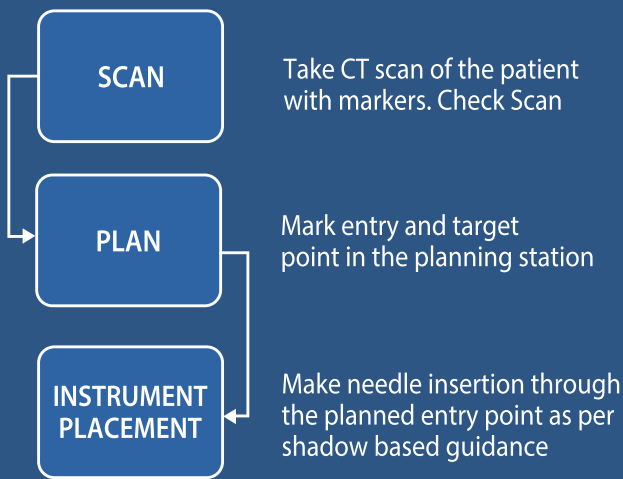
Circumvents dependency

- Target lesions of any size and location
- Help beginners to perform procedures seamlessly
- For any straight rigid instrument


Perform with better efficacy

- Accurate instrument placement
- Minimal iterations, reduced patient puncture and radiation
- Quick procedure, better scanner utilization
- Better patient and clinician comfort

Simple Workflow



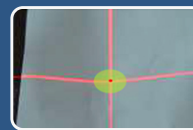Three Level Confirmation to ensure needle point accuracy



Laser cross hair to align to center of needle hub



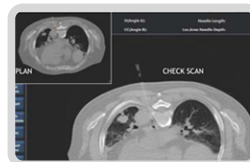All 4 needle shadows to be aligned to the laser cross hair



Needle hub to align to center of green circle on monitor

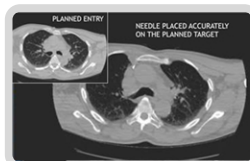Clinically Proven

Parameter	
Positioning accuracy	2 mm
% manipulations	3 %
Time taken to place needle	11 minutes
Average wheel in and wheel out time	26 minutes
*Average value calculated on 55 patient data	



Case Study 1 – Pain Management

Thoracic para vertebral block done for patient with intractable pleuritic pain. LP needle was placed precisely between aorta and T7 vertebra with HighNoon guidance.



Case Study 2 – Tru Cut Biopsy

Biopsy of small FDG avid node in front of SVC behind sternocostal junction accessed with craniolateral angulation between internal mammary vessels and aorta.